

Significance of MRI in rectal carcinoma therapy optimization – correlation of preoperative T- and N-staging with definitive histopathological findings

L. DANIHEL JR^{1,*}, L. DANIHEL SR², M. RAJČOK¹, K. MOSNA², V. BELAN³, I. VARGA⁴, M. SCHNORRER¹

¹3rd Surgical Clinic, Faculty of Medicine, Comenius University, Bratislava, Slovakia; ²Institute of Pathological Anatomy, Faculty of Medicine, Comenius University, Bratislava, Slovakia; ³Dr. Magnet – Kramare, Comenius University, Bratislava, Slovakia; ⁴Institute of Histology and Embryology, Faculty of Medicine, Comenius University, Bratislava, Slovakia

*Correspondence: l.danihel@gmail.com

Received May 22, 2018 / Accepted October 29, 2018

In past decades, both prognosis and therapy of rectal cancer patients showed significant improvement. On the other hand, the incidence of rectal carcinoma continues to have a rising tendency. According to current UICC classification, patients in stage II rectal cancer or higher are indicated for neoadjuvant chemoradiotherapy (nCRT). Magnetic resonance imaging (MRI) is currently the most common diagnostic method used for preoperative staging of rectal cancer. Several studies already pointed out the inaccuracy of preoperative lymph node staging in patients with rectal cancer. The present study analyzed overall accuracy of MRI staging of rectal cancer and thus its accuracy in neoadjuvant therapy indication, by comparing preoperative MRI staging with definitive histopathologic results from resected tumors. This study evaluated cases of 92 patients with rectal tumor that underwent MRI examination followed by surgical resection. Tumors included in the analysis were ranging from T1 to T3b according to the TNM staging, with free circumferential resection margin (CRM), distance from mesorectal fascia more than 5 mm, negative intersphincteric plane and also negative extramural venous invasion (EMVI), while the N stage was not decisive. In all cases, both N-staging and T-staging were evaluated histologically and compared with preoperative MRI results. Significant difference in preoperative and postoperative N-staging was shown in 51 patients (61.45%). In majority of cases MRI lead to over-staging, which was observed in 44 cases (53.1 %), with complete negativity of lymph nodes proven by histological examination in 34 cases. On the other hand, under-staging of lymph nodes was observed only in 7 cases (7.4 %). The T-staging did not show significant differences. Results from this study confirm that MRI plays an important role in T-staging of rectal tumors, however, there are undoubtedly issues in N-staging of tumors, which should lead to reevaluation of neoadjuvant therapy indication in patients with positive lymph nodes according to MRI examination. Based on the results of this study, we see the future of preoperative staging of rectal tumors in precise T-staging together with accurate assessment of CRM and distance of tumor from mesorectal fascia as well as evaluation of intersphincteric plane and EMVI.

Key words: rectal carcinoma, MRI, preoperative tumor staging, lymph node, histopathological findings

Colorectal carcinoma (CRC) is one of the most common neoplastic diseases in the developed world with continuing rising incidence. Statistically CRC represents 13% of all malignancies in human population and is the third most common malignancy in the countries of European Union, following lung and breast cancer in females or lung and prostate cancer in males [1]. The highest incidence of CRC amongst males is observed in central European countries, such as Slovakia, Hungary or the Czech Republic in contrast to very low rates in Greece and Cyprus. Among females, Denmark and The Netherlands have the highest incidence of CRC followed by Hungary and Slovakia, Greece and Finland have a low incidence [2].

At present, surgical associations recommend neoadjuvant therapy rather than adjuvant therapy in management of rectal cancer patients, based on the better survival rates of patients treated this way. Multimodal treatment of rectal cancer, with the combination of preoperative (neoadjuvant) chemoradiotherapy (nCRT) followed by surgical resection increases local control in locally advanced tumors and has become the standard approach to such rectal cancers [3–5]. Patients in stage I rectal cancer according to UICC (International Union Against Cancer) are indicated for primary surgical treatment, while stage II and higher rectal cancer patients are indicated for neoadjuvant therapy. Neoadjuvant therapy poses a great advance in the treatment of colorectal

cancer patients, nevertheless, it also bears negative side effects such as bowel emptying disorders, rectal inflammation or sexual dysfunctions. However, it is also important to take into account lower quality of life of patients undergoing neoadjuvant treatment [6]. Up to date information anticipate the possibility of selecting a group of patients that could profit from primary surgical resection of the tumor without neoadjuvant therapy by maintaining the same risk of recurrence, but achieving better quality of life of these patients.

Accurate preoperative staging of rectal cancer is the key to the correct patient management, however, current imaging techniques have limitations that considerably affect the therapeutic strategy. It is important to emphasize the tendency to over evaluate findings with the use of imaging techniques, especially in borderline cases, which leads to higher UICC stage and thus needless overtreatment of some patients. In the light of these issues, an alternative concept was developed that circumvents the problem of clinical TNM staging by a completely different approach, which focuses on determination of circumferential resection margin (CRM), distance from the mesorectal fascia and infiltration of the intersphincteric plane by magnetic resonance imaging (MRI) [7].

To address the issue of accuracy of clinical tumor staging in rectal cancer patients, which is in close connection to neoadjuvant therapy indication, we conducted a prospective study of 92 patients with resected rectal tumor in which we compared preoperative tumor staging based on MRI imaging with histological staging of resected tumors with emphasis on tumor and nodal staging.

Patients and methods

Patients. This study included 92 patients with rectal cancer that underwent primary tumor resection without neoadjuvant therapy. Out of 92 patients 42 were of female gender (45.7%) and 50 of male gender (54.3%). Indication to primary surgical tumor resection was decided upon preoperative MRI and all tumors were afterwards examined histologically. The patient data in this study were obtained from hospital documentation of 3rd Surgical Clinic of Comenius University in Bratislava from September 2013 to September 2017. The medical records of these patients were analyzed after ethics committee approval. Patients were further classified into three groups according to the distance of tumor from anus; low rectal tumors (0–6 cm from anus), mid rectal tumors (6–12 cm) and upper rectal tumors (12–16 cm).

Methods. Prior to the surgical resection all patients underwent MRI examination aimed at tumor staging. Tumor stage was assigned according to 2009 TNM classification. This study included tumors ranging from T1 to T3b stage according to this classification while the N stage was not considered. Other factors evaluated by MRI that were taken into consideration when choosing patients for the study was free circumferential resection margin (mrCRM), distance from mesorectal fascia more than 5 mm as well as free inter-

sphincteric plane. All patients underwent the same range of examination in the same hospital departments.

Surgical resection was followed by histopathological examination of resected specimen, that lead to definite tumor classification as well as pathological TNM staging (pTNM). This study included patients with at least 12 histologically examined sentinel lymph nodes. During the histopathological evaluation distance from mesorectal fascia was measured as well. The histologic type or grade of the tumor were not taken into consideration.

Preoperative histological examination verified high grade dysplasia in 9 cases with invasive carcinoma characteristics on MRI. Postoperative histological examination of these cases confirmed benign character of the lesions. This group represented overestimation in MRI examination and was excluded from final statistical evaluation.

Statistical analysis. Collected data were evaluated statistically using Fisher's Exact test to determine differences in the representation of individual data, while the difference in the representation of the data obtained from two different approaches was based on Chi-Squared test. The results were considered statistically significant when p value was < 0.05.

Results

Patient characteristics. Since in 9 patients, from the initial group of 92, benign characteristic of the rectal lesion was diagnosed after histopathological examination of resected tissue, they had to be excluded from the statistical analysis. In the further evaluation data from 83 patients were processed. The average age of patients was 67.9 years with a standard deviation of 9.47. Due to intraoperative findings a protective stoma was placed in 21 patients. Group of patients with low rectal tumor comprised 22 patients (27%), the most extensive group with mid rectal tumor consisted of 52 patients (63%) and group with upper rectal tumor consisted of 9 patients (10%).

T-staging evaluation. When comparing the accuracy of preoperative MRI and definitive histopathologic examination with the focus on T staging, the overall success rate was 62% with overestimation in 22% and underestimation in 16% of cases. The comparison of results in the three different compartments of rectum showed the highest accuracy of preoperative MRI in patients with low rectal tumors, represented by 73% (16 patients). Accuracy of MRI examination in tumors of mid rectum reached 60% (31 patients) and upper rectal tumors 55% (5 patients). In the overall T-staging accuracy we have not observed statistically significant difference ($p > 0.06$).

The final results showed over-staging using MRI examination in 24% cases with mid rectal cancer (12 patients) and in 18% with lower and upper rectal cancer (4 and 2 patients respectively). Tumor under-staging was seen in 27% of patients with upper rectal cancer (2 patients), 16% of mid rectal cancer (9 patients) and 9% of low rectal cancer (2

patients). In the investigated group of patients there was not a significant difference in T-staging in any rectal compartment ($p>0.08$) (Figure 1). Most evident difference in preoperative staging and definite histopathological T-staging was observed in T2–T3b tumor stage group.

N-staging evaluation. N-staging in preoperative diagnosis of rectal cancer is currently one of the most discussed topics. Through MRI examination it is possible to estimate the increase in lymph node size, however, it is not possible to specify if the enlargement is a result of metastases or reactive changes. In lymph node evaluation we included only patients with histologically verified invasive carcinoma (83 patients). The preoperative MRI examination and postoperative histological evaluation of lymph nodes showed conformity in 32 cases (39.5%). In majority of cases MRI lead to over-staging of lymph nodes, which was observed in 44 cases (53.1%), with complete negativity of lymph nodes proven by histological examination in 34 cases. On the other hand, under-staging of lymph nodes was observed only in 7 cases (7.4%). The results proved statistically significant differences in N-staging ($p=0.03$).

The comparison of results of MRI examination and histopathological examination of lymph nodes showed the highest accuracy of N-staging in mid rectal tumors – 46% (25 patients). Compatible results of N-staging were yield in 27% of patients in lower and upper rectal tumors (4 and 3 patients respectively). The most common problem in clinical praxis is over-staging of lymph nodes, which was proven by the analysis as well. Lymph node over-staging was most common in lower rectal tumor patients – 73% (18 patients). In upper rectal tumors the over-staging was in 55% cases (4 patients) and in mid rectal tumors in 44% (22 patients). Under-staging of lymph nodes was noted in 2 patients with upper rectal tumor (18%) and 5 patients with mid rectal tumor (10%) while no under-staging of lymph nodes was observed in patients with low rectal tumors (Figure 2). Statistically significant difference in N-staging was noted in patients with low rectal tumors ($p<0.03$).

Mesorectal fascia distance. All patients included in this study fulfilled criteria of “good prognosis”, with preoperative distance of tumor from mesorectal fascia at least 5 mm. Analysis of histopathological results did not show infiltration of mesorectal fascia in any of the 83 patients. The exact distance of tumors from mesorectal fascia was obtained only later throughout the study. To prevent misinterpretation of the results, further analysis of accuracy of preoperative measurements of mesorectal distances was not pursued.

Discussion

In the diagnosis of rectal tumors, thorough anamnesis remains the golden standard that should lead the doctor to choose the correct patient management. The tumor staging is assessed through combination of endoscopic examination and imaging techniques. A rising number of therapeutic

choices for RC is accompanied by three different staging modalities: EUS, CT, and MRI. All these modalities have their benefits and specific limitations restricting overall performance [8]. Current worldwide tendency is individual multi-disciplinary patient care as well as the effort to maintain the highest possible comfort with the lowest recurrence rate of the disease. According to up-to-date guidelines the patients in stage I rectal cancer are indicated to primary surgical resection, while patients in stage II and higher to neoadjuvant therapy. UICC staging is assigned mainly according to MRI results, which represents the standard imaging examination in staging of rectal cancer. MRI shows high resolution of soft tissues, however, the accurate distinction of borderline T2–3 tumors remains an issue due to the excessive growth of dense fibrous tissue around the tumor (desmoplastic reaction), which makes it hard to assess the exact expansion of tumor. In our analysis, we similarly proved the highest mistake rate in T-staging in borderline T2–3 tumors.

Present-day protocols of MRI examination are taking into account assessment of the circumferential resection margin as well as allocation of the exact distance of tumor from mesorectal fascia. 5 mm distance of tumor from mesorectal

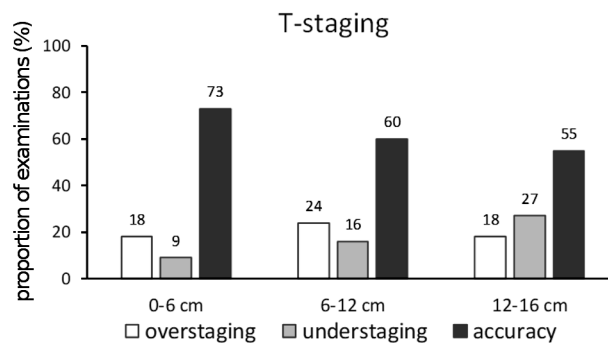


Figure 1. T-Staging accuracy of preoperative MRI examination in different parts of rectum, no significant difference was observed – ns ($p>0.08$). Statistically significant difference wasn't detected in the overall N-staging accuracy ($p>0.06$)

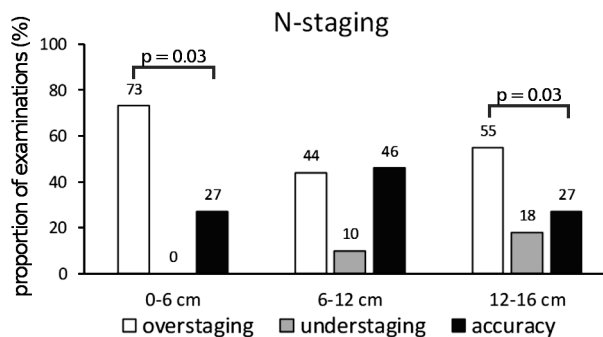


Figure 2. N-Staging accuracy of preoperative MRI examination, in different parts of rectum, * $p<0.03$, ns ($p>0.04$). Statistically significant difference ($p=0.03$) was detected in the overall N-staging accuracy.

Table 1. Parameters of good and poor prognosis of rectal cancer patients according to The Magnetic Resonance Imaging and Rectal Cancer European Equivalence (MERCURY) Study (modification after [12]).

MRI	Good prognosis	Poor prognosis
CRM	>1 mm	<1 mm
Tumors of lower rectum < 5cm from anus	Intersphincteric plane without tumor infiltration	Intersphincteric plane with tumor infiltration
T-staging	T1/T2 T3a <1 mm T3b <1–5 mm	T3c >5 mm T4
EMVI	Negative	Positive
N-staging	Any stage	Any stage

fascia measured on MRI images correlates with 1 mm free edge in histopathological examination [9]. The involvement of the CRM is an important prognostic indicator of appearance of local recurrences [10]. According to the meta-analysis of Al-Sukhni the CRM examination by MRI distinguishes 77% sensitivity and 94% specificity [11].

The accurate assessment of T-staging of tumor, CRM and distance from mesorectal fascia are key factors in correct patient management. Other important aspects to take into account are the evaluation of intersphincteric plane and extramural venous invasion (EMVI), which could distinguish patients with better prognosis that might benefit from primary surgical resection (Table 1). Intersphincteric plane is recognized region starting approximately 1 cm above puborectal sling that is being evaluated during MRI examination for possible tumor infiltration. According to the MERCURY study, patients with not clearly free intersphincteric plane showed 17-fold higher risk of tumor positive CRM compared to patients with free intersphincteric plane [12]. Preoperative MRI assessment of low rectal cancer surgical resection plane (mrLRP) can also aid in correct treatment choice. Assessment of mrLRP evaluates mesorectal fascia and intersphincteric plane. When the distance of tumor from mesorectal fascia is at least 1 mm the mrLRP is considered “safe”, while infiltration of mesorectal fascia and /or intersphincteric plane is deemed “unsafe” mrLRP. Another emerging factor that might be important in patient management evaluation is determining extramural venous invasion, which is defined as presence of tumor cells in vessels beyond muscularis propria. Classically EMVI is evaluated during histopathological examination, however, it has been recently proved that EMVI can be easily identified by MRI as well. Statistically, this method shows around 62% sensitivity and 88% specificity [13].

The results of current studies anticipate changes in therapeutic schemes of rectal cancer patients. Recently, the MERCURY study group published a series of patients receiving surgery without neoadjuvant chemoradiotherapy (nCRT) who were selected by mrCRM and several other criteria which were based on preoperative magnetic

resonance imaging. In this series, local recurrence rate was 3.3% after 3 years [12]. Statistically, there is considerable inaccuracy in lymph node staging in tumors of mid and lower rectum, which is supported by our study as well. Inaccuracy of lymph node staging by MRI shows such a high mistake rate. During the ESGAR meeting in 2016, it was proposed to completely eliminate the preoperative lymph node staging in patients with good prognosis – T staging lesser than T3b, no infiltration of mesorectal fascia and free mrCRM [14]. Our study showed only 39.5% success rate in lymph node staging which further proves the limitations of MRI examination in discriminating metastatic lymph nodes from reactive ones. From 44 patients with over-staging of lymph nodes on MRI examination, the histological evaluation of lymph nodes showed a complete negativity in 34 cases. The highest rate of misinterpretation of lymph node staging was noted in patients with low and upper rectal cancer. Under-staging of lymph nodes has not proved to be statistically significant in our study. In clinical praxis, the theory starts to be adapted that upper rectal tumors should undergo the same management as tumors of colon. On the other hand, according to Zhou et al. that compared MRI with histological evaluation of lymph nodes while using irregular morphology and signal characteristics to determine nodal status, MRI was 45–85% sensitive, 83–100% specific and had a 72% positive predictive value, 71% negative predictive value and 64% accuracy for node positive disease [15].

High-resolution T2-weighted MRI is less accurate in restaging rectal cancer following chemoradiotherapy as compared to initial staging, because of post-therapeutic fibrosis and inflammation [16]. However, the evolution of diffusion-weighted imaging leads to marked advance in accurate diagnosis and evaluation of residual tissue [17], which shows an important role of MRI in rectal cancer restaging as well.

Our analysis unambiguously proved the importance of magnetic resonance imaging in diagnosis of rectal cancer. This imaging method plays an important role in T-staging of rectal tumors, however, there are admittedly issues in N-staging of tumors which should lead to re-evaluation of neoadjuvant therapy in patients with MRI positive lymph nodes. Adding functional MR sequences such as dynamic contrast-enhanced and diffusion-weighted sequences to the standard approach can improve diagnostic accuracy of MRI [18–20]. New emerging parameters interpreted during MRI examination like CRM, EMVI or distance of tumor from mesorectal fascia postulate better accuracy in preoperative staging as well.

We see the future of preoperative staging of rectal tumors in accurate T-staging together with assessing the circumferential resection margin and distance of tumor from mesorectal fascia. The result of our analysis supported by numerous other international studies (for example MERCURY study) shows the importance of revising the current guidelines. The present international study does not yet report local recur-

rence rate or other parameters of oncologic outcome that are anxiously awaited and are going to be the subject of following prospective studies.

References

- [1] FERLAY J, STELIAROVA-FOUCHER E, LORTET-TIEULENT J, ROSSO S, COEBERGH JW et al. Cancer incidence and mortality patterns in Europe: estimates for 40 countries in 2012. *Eur J Cancer* 2013; 49: 1374–1403. <https://doi.org/10.1016/j.ejca.2012.12.027>
- [2] VAN DE VELDE CJ, BOELENS PG, BORRAS JM, COEBERGH JW, CERVANTES A et al. EURECCA colorectal: multidisciplinary management: European consensus conference colon & amp; rectum. *Eur J Cancer* 2014; 50: 1.e1–1.e34. <https://doi.org/10.1016/j.ejca.2013.06.048>
- [3] WATANABE T, ITABASHI M, SHIMADA Y, TANAKA S, ITO Y et al. Japanese Society for Cancer of the Colon and Rectum (JSCCR) Guidelines 2014 for treatment of colorectal cancer. *Int J Clin Oncol* 2015; 20: 207–239. <https://doi.org/10.1007/s10147-015-0801-z>
- [4] MONSON JR, WEISER MR, BUIE WD, CHANG GJ, RAFFERTY JF et al. Practice parameters for the management of rectal cancer (revised). *Dis Colon Rectum* 2013; 56: 535–550. <https://doi.org/10.1097/DCR.0b013e31828cb66c>
- [5] MILLARD T, KUNK PR, RAMSDALE E, RAHMA OE. Current debate in the oncologic management of rectal cancer. *World J Gastrointest Oncol* 2016; 8: 715–724. <https://doi.org/10.4251/wjgo.v8.i10.715>
- [6] FOLKESSON J, BIRGISSON H, PAHLMAN L, CEDERMARK B, GLIMELIUS B et al. Swedish Rectal Cancer Trial: long lasting benefits from radiotherapy on survival and local recurrence rate. *J Clin Oncol* 2005; 24: 5644–5650. <https://doi.org/10.1200/JCO.2005.08.144>
- [7] KREIS ME, RUPPERT R, PTOK H, STRASSBURG J, BROSI P et al. Use of Preoperative Magnetic Resonance Imaging to Select Patients with Rectal Cancer for Neoadjuvant Chemoradiation – Interim Analysis of the German OCUM Trial (NCT01325649). *J Gastrointest Surg* 2016; 20: 25–32. <https://doi.org/10.1007/s11605-015-3011-0>
- [8] SCHEELE J, SCHMIDT SA, TENZER S, HENNE-BRUNS D, KORNMANN M. Overstaging: A Challenge in Rectal Cancer Treatment. *Visc Med* 2018; 34: 301–306. doi: 10.1159/000488652
- [9] BEETS-TAN RG, BEETS GL, VLIEGEN RF, KESSELS AG, VAN BOVEN H et al. Accuracy of magnetic resonance imaging in prediction of tumor free resection margin in rectal cancer surgery. *Lancet* 2001; 357: 497–504. [https://doi.org/10.1016/S0140-6736\(00\)04040-X](https://doi.org/10.1016/S0140-6736(00)04040-X)
- [10] IAFRATE F, LAGHI A, PAOLANTONIO P, RENGO M, MERCANTINI P et al. Preoperative staging of rectal cancer with MR Imaging: correlation with surgical and histopathologic findings. *Radiographics* 2006; 26: 701–714. <https://doi.org/10.1148/rg.263055086>
- [11] AL-SUKHNI E, MILOT L, FRUITMAN M, BEYENE J, VICTOR JC et al. Diagnostic accuracy of MRI for assessment of T category, lymph node metastases and circumferential resection margin involvement in patients with rectal cancer: a systematic review and meta-analysis. *Ann Surg Oncol* 2012; 19: 2212–2223. <https://doi.org/10.1245/s10434-011-2210-5>
- [12] TAYLOR FG, QUIRKE P, HEALD RJ, MORAN BJ, BLOMQVIST L et al. Preoperative magnetic resonance imaging assessment of circumferential resection margin predicts disease-free survival and local recurrence: 5-year follow-up results of the MERCURY study. *J Clin Oncol* 2014; 32: 34–43. <https://doi.org/10.1200/JCO.2012.45.3258>
- [13] KREIS ME, STRASSBURG J (Eds.). *Moderne Chirurgie des Rektumkarzinoms*. Springer-Verlag Berlin, 2015. ISBN 978-3-642-40389-7.
- [14] BEETS-TAN RGH, LAMBREGTS DMJ, MAAS M, BIPAT S, BARBARO B et al. Magnetic resonance imaging for clinical management of rectal cancer: Updated recommendations from the 2016 European Society of Gastrointestinal and Abdominal Radiology (ESGAR) consensus meeting. *Eur Radiol* 2018; 28: 1465–1475. <https://doi.org/10.1007/s00330-017-5026-2>
- [15] ZHOU J, ZHAN S, ZHU Q, GONG H, WANG Y et al. Prediction of nodal involvement in primary rectal carcinoma without invasion to pelvic structures: accuracy of preoperative CT, MR, and DWIBS assessments relative to histopathologic findings. *PLoS One*; 2014; 9: e92779. <https://doi.org/10.1371/journal.pone.0092779>
- [16] JHAVERI KS, HOSSEINI-NIK H. MRI of Rectal Cancer: An Overview and Update on Recent Advances. *AJR Am J Roentgenol* 2015; 205: W42–W55. <https://doi.org/10.2214/AJR.14.14201>
- [17] HOTKER A, GARCIA-AGUILAR J, GOLLUB MJ. Multiparametric MRI of rectal cancer in the assessment of response to therapy: a systematic review. *Dis Colon Rectum* 2014; 57: 790–799. <https://doi.org/10.1097/DCR.0000000000000127>
- [18] KIM SH, LEE JY, LEE JM, HAN JK, CHOI BI. Apparent diffusion coefficient for evaluating tumour response to neoadjuvant chemoradiation therapy for locally advanced rectal cancer. *Eur Radiol* 2011; 21: 987–995. <https://doi.org/10.1007/s00330-010-1989-y>
- [19] SUN YS, ZHANG XP, TANG L, JI JF, GU J et al. Locally advanced rectal carcinoma treated with preoperative chemotherapy and radiation therapy: preliminary analysis of diffusion-weighted MR imaging for early detection of tumor histopathologic downstaging. *Radiology* 2010; 254: 17–178. <https://doi.org/10.1148/radiol.2541082230>
- [20] ENGIN G, SHARIFOV R, GURAL Z, SAGAM EK, SAGLAM S et al. Can diffusion-weighted MRI determine complete responders after neoadjuvant chemoradiation for locally advanced rectal cancer? *Diagn Interv Radiol* 2012; 18: 574–581. <https://doi.org/10.4261/1305-3825.DIR.5755-12.1>